

THIEME

Latin Nomenclature

Atlas of Anatomy

Volume 2
Internal Organs

Michael Schuenke
Erik Schulte
Udo Schumacher

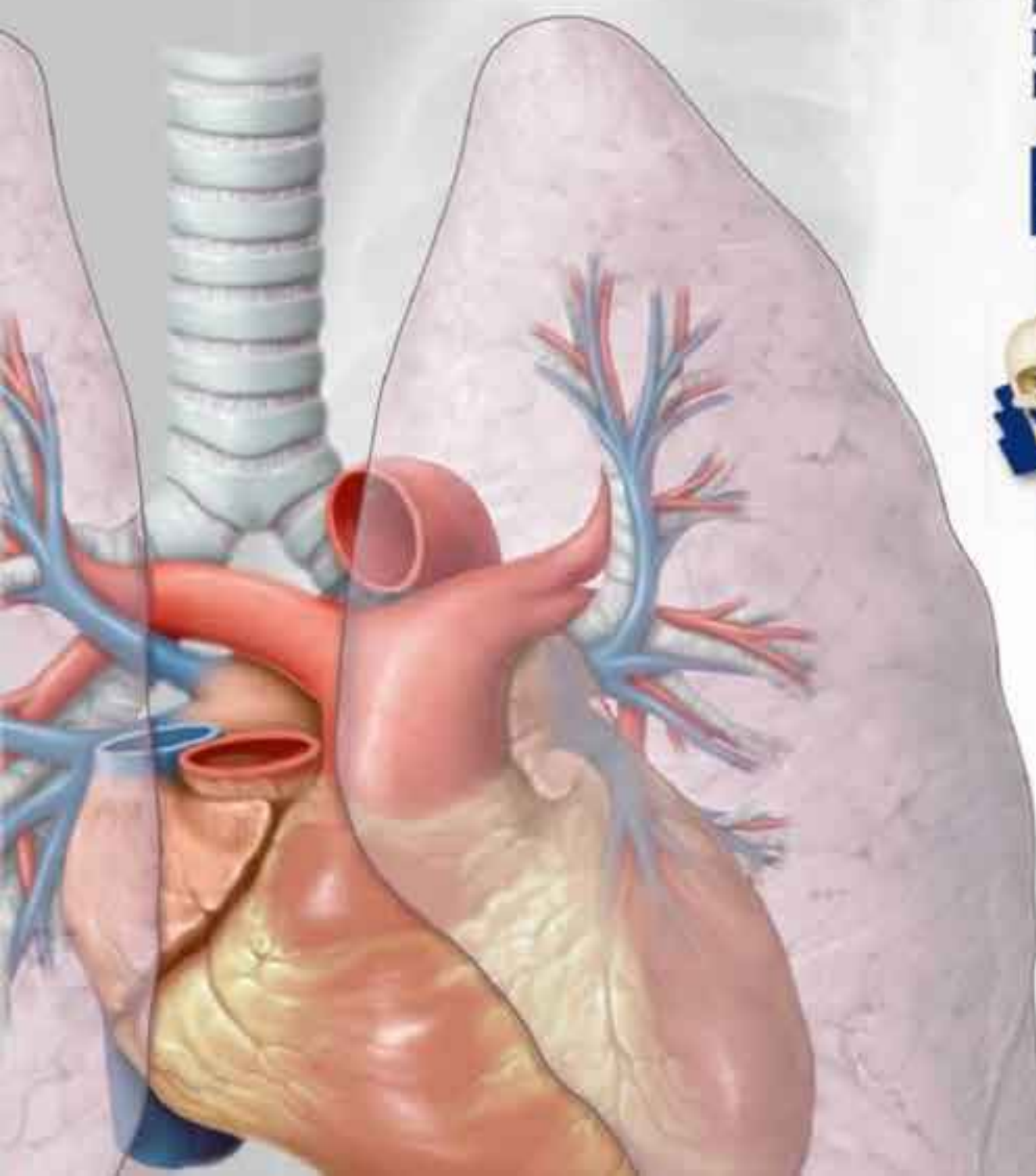
Consulting Editors
Wayne A. Cass
Hugo Zeberg

Illustrations by
Markus Voll
Karl Wesker

Second Edition

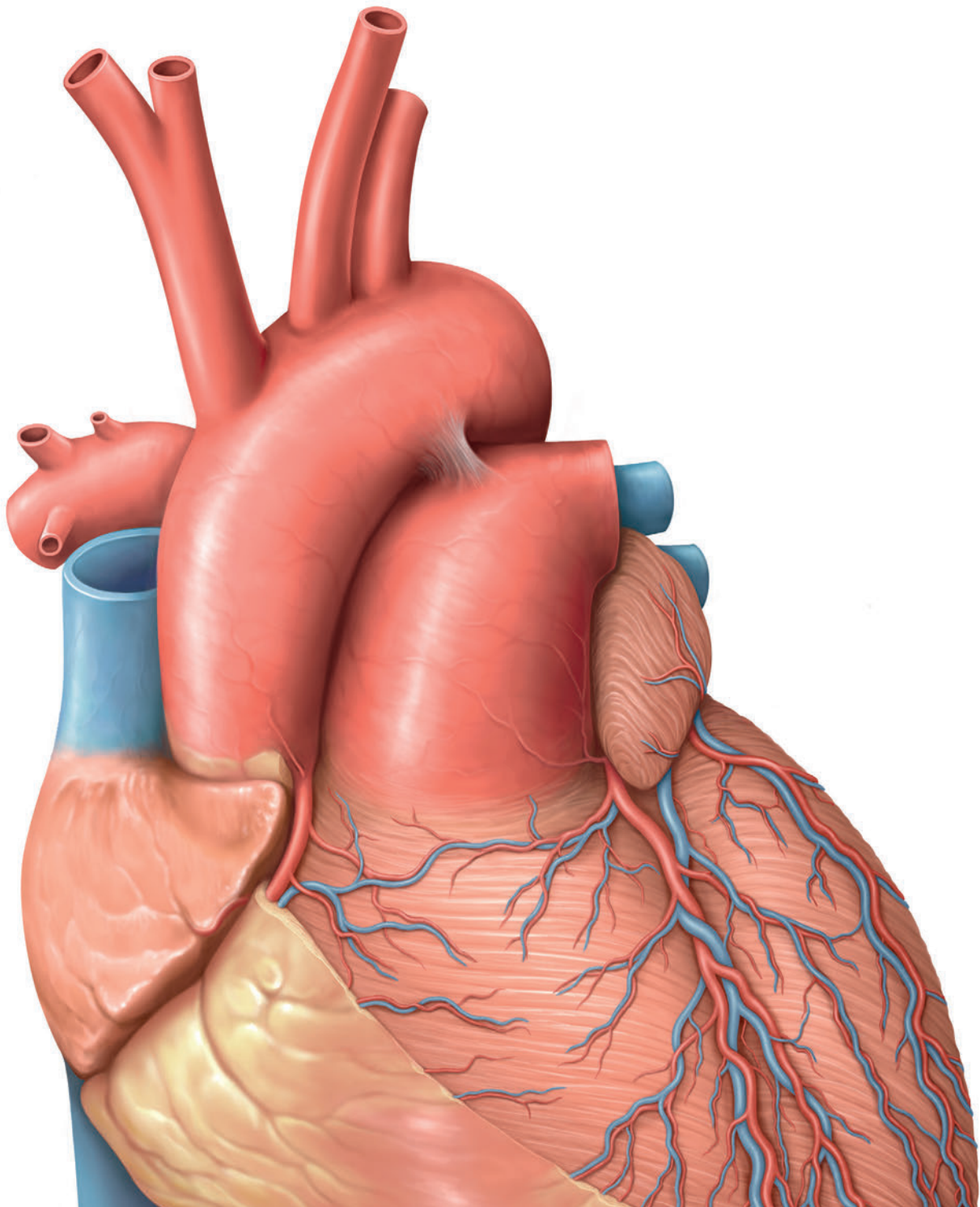


Includes online
self-testing tool!
www.winkingskull.com



 Thieme

To access additional material or resources available with this e-book, please visit <http://www.thieme.com/bonuscontent>. After completing a short form to verify your e-book purchase, you will be provided with the instructions and access codes necessary to retrieve any bonus content.



Volume 2

Internal Organs

THIEME Atlas of Anatomy

Second Edition

Latin Nomenclature

Authors

Michael Schuenke, MD, PhD
Institute of Anatomy
Christian Albrecht University, Kiel

Erik Schulte, MD
Department of Anatomy and Cell Biology
Johannes Gutenberg University, Mainz

Udo Schumacher, MD
FRCPath, CBiol, FIBiol, DSc
Institute of Anatomy II: Experimental Morphology
University Medical Center, Hamburg-Eppendorf

Consulting Editors

Wayne A. Cass, PhD
Professor and Director of Graduate Studies
Department of Anatomy and Neurobiology
University of Kentucky

Hugo Zeberg, MD, PhD
Lecturer
Department of Neuroscience
Karolinska Institutet
Stockholm, Sweden

Illustrations by

Markus Voll
Karl Wesker

Thieme
New York • Stuttgart • Delhi • Rio de Janeiro

Editorial Director, Educational Products: Anne M. Sydor
Editorial Assistant: Tony Paese
Managing Editor: Judith Tomat
Director, Editorial Services: Mary Jo Casey
International Production Director: Andreas Schabert
Vice President, Editorial and E-Product Development: Vera Spillner
International Marketing Director: Fiona Henderson
International Sales Director: Louisa Turrell
Director of Sales, North America: Mike Roseman
Senior Vice President and Chief Operating Officer: Sarah Vanderbilt
President: Brian D. Scanlan
Illustrations: Markus Voll and Karl Wesker
Compositor: Agnieszka & Martin Waletzko, Leonberg, Germany

**Library of Congress Cataloging-in-Publication Data
is available from the publisher upon request.**

Copyright ©2017 by Thieme Medical Publishers, Inc.

Thieme Publishers New York
333 Seventh Avenue, New York, NY 10001 USA
+1 800 782 3488, customerservice@thieme.com

Thieme Publishers Stuttgart
Rüdigerstrasse 14, 70469 Stuttgart, Germany
+49 [0]711 8931 421, customerservice@thieme.de

Thieme Publishers Delhi
A-12, Second Floor, Sector-2, Noida-201301
Uttar Pradesh, India
+91 120 45 566 00, customerservice@thieme.in

Thieme Publishers Rio de Janeiro,
Thieme Publicações Ltda.
Edifício Rodolpho de Paoli, 25º andar
Av. Nilo Peçanha, 50 – Sala 2508
Rio de Janeiro 20020-906, Brasil
+55 21 3172 2297

Important note: Medicine is an ever-changing science undergoing continual development. Research and clinical experience are continually expanding our knowledge, in particular our knowledge of proper treatment and drug therapy. Insofar as this book mentions any dosage or application, readers may rest assured that the authors, editors, and publishers have made every effort to ensure that such references are in accordance with **the state of knowledge at the time of production of the book.**

Nevertheless, this does not involve, imply, or express any guarantee or responsibility on the part of the publishers in respect to any dosage instructions and forms of applications stated in the book. **Every user is requested to examine carefully** the manufacturers' leaflets accompanying each drug and to check, if necessary in consultation with a physician or specialist, whether the dosage schedules mentioned therein or the contraindications stated by the manufacturers differ from the statements made in the present book. Such examination is particularly important with drugs that are either rarely used or have been newly released on the market. Every dosage schedule or every form of application used is entirely at the user's own risk and responsibility. The authors and publishers request every user to report to the publishers any discrepancies or inaccuracies noticed. If errors in this work are found after publication, errata will be posted at www.thieme.com on the product description page.


Some of the product names, patents, and registered designs referred to in this book are in fact registered trademarks or proprietary names even though specific reference to this fact is not always made in the text. Therefore, the appearance of a name without designation as proprietary is not to be construed as a representation by the publisher that it is in the public domain.

Printed in China by Everbest Printing Ltd

5 4 3 2 1

ISBN 978-1-62623-167-2

Also available as an e-book:
eISBN 978-1-62623-168-9



This book, including all parts thereof, is legally protected by copyright. Any use, exploitation, or commercialization outside the narrow limits set by copyright legislation, without the publisher's consent, is illegal and liable to prosecution. This applies in particular to photostat reproduction, copying, mimeographing, preparation of microfilms, and electronic data processing and storage.

Contents

| | |
|---|------|
| Foreword by Lawrence M. Ross, Brian R. MacPherson, and Anne M. Gilroy | XI |
| Preface to the Second Edition | XIII |
| Preface to the First Edition | XV |
| A Note on the Use of Latin Terminology | XVI |
| Acknowledgments | XVII |

Structure and Development of Organ Systems

1 Body Cavities

| | |
|---|---|
| 1.1 Definitions, Overview, and Evolution of Body Cavities | 2 |
| 1.2 Organogenesis and the Development of Body Cavities | 4 |
| 1.3 Compartmentalization of the Coeloma Intraembryonicum | 6 |
| 1.4 Organization and Architecture of Body Cavities | 8 |

2 Cardiovascular System

| | |
|---|----|
| 2.1 Overview and Basic Wall Structure | 10 |
| 2.2 Terminal Vessels and Overview of the Major Blood Vessels | 12 |
| 2.3 Cardiogenic Area, Development of the Heart Tube | 14 |
| 2.4 Development of the Inner Chambers of the Heart and Fate of the Sinus Venosus | 16 |
| 2.5 Cardiac Septation (Formation of Septa Interatriale, Interventriculare, and Aorticopulmonale). | 18 |
| 2.6 Pre- and Postnatal Circulation and Common Congenital Heart Defects | 20 |

3 Respiratory System

| | |
|---|----|
| 3.1 Overview of the Respiratory System | 22 |
| 3.2 Development of the Larynx, Trachea, and Lungs | 24 |
| 3.3 Lung Development and Maturation | 26 |

4 Digestive System

| | |
|--|----|
| 4.1 Overview of the Digestive System | 28 |
| 4.2 Development and Differentiation of the Gastrointestinal Tract | 30 |
| 4.3 Mesenteria and Primordia of the Digestive Organs in the Caudal Praeenteron Region; Stomach Rotation | 32 |
| 4.4 Stomach Rotation and Organ Location in the Caudal Praeenteron Region; Formation of the Bursa Omentalis | 34 |
| 4.5 Rotation of the Intestinal Loop and Development of Mesenteron and Metenteron Derivatives | 36 |
| 4.6 Summary of the Development of the Mesenteron and Metenteron; Developmental Anomalies | 38 |

5 Urinary System

| | |
|--|----|
| 5.1 Overview of the Urinary System | 40 |
| 5.2 Development of the Renes, Pelvis Renalis, and Ureteres | 42 |
| 5.3 Development of Nephrons, and the Vesica Urinaria and Ureteres; Developmental Anomalies | 44 |

6 Genital System

| | |
|---|----|
| 6.1 Overview of the Genital System | 46 |
| 6.2 Development of the Gonadae | 48 |
| 6.3 Development of the Ductus Genitales | 50 |
| 6.4 Comparison of Gender Differences and Relationship to the Urinary System | 52 |
| 6.5 Comparison of Embryonic and Mature Structures | 54 |

7 Lymphatic System

| | |
|--|----|
| 7.1 Overview of the Lymphatic System | 56 |
| 7.2 Lymphatic Drainage Pathways | 58 |

8 Endocrine System

| | |
|---|----|
| 8.1 Overview of the Endocrine System | 60 |
| 8.2 Metabolism and Feedback Loop Regulation in the Endocrine System | 62 |

9 Autonomic Nervous System

| | |
|--|----|
| 9.1 The Sympathetic and Parasympathetic Nervous Systems | 64 |
| 9.2 Afferent Pathways of the Autonomic Nervous System and the Enteric Nervous System | 66 |

Thorax

10 Overview and Diaphragma

| | | |
|------|--|----|
| 10.1 | Divisions of the Cavitas Thoracica and Mediastinum | 70 |
| 10.2 | Diaphragma: | |
| | Location and Projection onto the Trunk | 72 |
| 10.3 | Structure and Main Openings | 74 |
| 10.4 | Innervation, Blood and Lymphatic Vessels | 76 |

11 Overview of Neurovascular Structures

| | | |
|------|------------------------------------|----|
| 11.1 | Arteries: Aorta Thoracica | 78 |
| 11.2 | Veins: Vena Cava and Azygos System | 80 |
| 11.3 | Vasa Lymphatica | 82 |
| 11.4 | Nodi Lymphoidei Thoracis | 84 |
| 11.5 | Thoracic Innervation | 86 |

12 Organs of the Cardiovascular System and their Neurovasculature

| | | |
|-------|---|-----|
| 12.1 | Location of the Heart (Cor) in the Thorax | 88 |
| 12.2 | Pericardium: Location, Structure, and Innervation | 90 |
| 12.3 | Cor: Shape and Structure | 92 |
| 12.4 | Structure of the Cardiac Musculature (Myocardium) | 94 |
| 12.5 | Cardiac Chambers | 96 |
| 12.6 | Overview of the Cardiac Valves (Valve Plane and Cardiac Skeleton) | 98 |
| 12.7 | Cardiac Valves and Auscultation Sites | 100 |
| 12.8 | Radiographic Appearance of the Cor | 102 |
| 12.9 | Sonographic Appearance of the Cor: | |
| | Echocardiography | 104 |
| 12.10 | Magnetic Resonance Imaging (MRI) of the Cor | 106 |
| 12.11 | Impulse Formation and Conduction System of the Cor; Electrocardiogram | 108 |
| 12.12 | Mechanical Action of the Cor | 110 |
| 12.13 | Arteriae Coronariae and Venae cordis: | |
| | Classification and Topography | 112 |
| 12.14 | Arteriae Coronariae: Coronary Circulation | 114 |
| 12.15 | Coronary Heart Disease (CHD) and Heart Attack | 116 |
| 12.16 | Conventional Coronary Angiography (Heart Catheter Examination) | 118 |
| 12.17 | Multislice Spiral Computed Tomography (MSCT) Coronary Angiography | 120 |
| 12.18 | Balloon Dilatation, Aortocoronary Venous and Arterial IMA Bypass | 122 |
| 12.19 | Lymphatic Drainage of the Cor | 124 |
| 12.20 | Innervation of the Cor | 126 |

13 Organs of the Respiratory System and their Neurovasculature

| | | |
|------|---|-----|
| 13.1 | Lungs: Location in the Thorax | 128 |
| 13.2 | Cavitates Pleurales | 130 |
| 13.3 | Boundaries of the Lungs and Pleura Parietalis | 132 |

| | | |
|-------|---|-----|
| 13.4 | Trachea | 134 |
| 13.5 | Lungs: | |
| | Shape and Structure | 136 |
| 13.6 | Segmentation | 138 |
| 13.7 | Functional Structure of the Arbor Bronchialis | 140 |
| 13.8 | Arteriae and Venae Pulmonales | 142 |
| 13.9 | Rami and Venae Bronchiales | 144 |
| 13.10 | Functional Structure of the Vascular Tree | 146 |
| 13.11 | Innervation and Lymphatic Drainage of the Trachea, Arbor Bronchialis, and Lungs | 148 |
| 13.12 | Respiratory Mechanics | 150 |
| 13.13 | Radiological Anatomy of the Lungs and Vascular System | 152 |
| 13.14 | Computed Tomography of the Lungs | 154 |

14 Oesophagus and Thymus and their Neurovasculature

| | | |
|------|---------------------------------------|-----|
| 14.1 | Oesophagus: | |
| | Location and Divisions | 156 |
| 14.2 | Inlet and Outlet, Opening and Closure | 158 |
| 14.3 | Wall Structure and Weaknesses | 160 |
| 14.4 | Arteries and Veins of the Oesophagus | 162 |
| 14.5 | Lymphatic Drainage of the Oesophagus | 164 |
| 14.6 | Innervation of the Oesophagus | 166 |
| 14.7 | Thymus | 168 |

15 Topographical Anatomy

| | | |
|-------|--|-----|
| 15.1 | Surface Anatomy, Topographical Regions, and Palpable Bony Landmarks | 170 |
| 15.2 | Anatomical Landmarks of the Skeleton Thoracis (Projection of Organs) | 172 |
| 15.3 | Structure of the Anterior Thoracic Wall and its Neurovascular Structures | 174 |
| 15.4 | Thoracic Organs in situ: | |
| | Anterior, Lateral, and Inferior Views | 176 |
| | Posterior Views | 178 |
| 15.5 | Cor: Cavitas Pericardiaca | 180 |
| 15.6 | Overview of the Mediastinum | 182 |
| 15.7 | Mediastinum Posterius | 184 |
| 15.8 | Mediastinum Superius | 186 |
| 15.9 | Arcus Aortae and Apertura Thoracis Superior | 188 |
| 15.10 | Clinical Aspects: | |
| | Coarctation of the Aorta | 190 |
| 15.11 | Aortic Aneurysm | 192 |

Abdomen and Pelvis

16 Structure of the Cavitas Abdominis and Cavitas Pelvis: Overview

- 16.1 Architecture, Wall Structure, and Functional Aspects 196
- 16.2 Divisions of the Cavitas Abdominis and Cavitas Pelvis 198
- 16.3 Classification of Internal Organs Based on their Relationship to the Cavitas Abdominis and Cavitas Pelvis . 200

17 Overview of Neurovascular Structures

- 17.1 Branches of the Aorta Abdominalis:
 - Overview and Paired Branches. 202
- 17.2 Unpaired and Indirect Paired Branches 204
- 17.3 Inferior Vena Caval System 206
- 17.4 Portal Venous System (Vena Portae Hepatis) 208
- 17.5 Venous Anastomoses in the Abdomen and Pelvis 210
- 17.6 Trunci Lymphatici and Nodi Lymphoidei 212
- 17.7 Overview of the Lymphatic Drainage of Abdominal and Pelvic Organs 214
- 17.8 Autonomic Ganglia and Plexuses. 216
- 17.9 Organization of the Partes Sympathica and Parasympathica of the Nervous System 218

18 Organs of the Digestive System and their Neurovasculature

- 18.1 Gaster:
 - Location, Shape, Divisions, and Interior View 220
- 18.2 Wall Structure and Histology 222
- 18.3 Intestinum Tenue:
 - Duodenum 224
- 18.4 Jejunum and Ileum 226
- 18.5 Intestinum Crassum:
 - Colon Segments 228
- 18.6 Wall Structure, Caecum, and Appendix Vermiformis . . . 230
- 18.7 Location, Shape, and Interior View of Rectum 232
- 18.8 Continence Organ:
 - Structure and Components 234
 - Function. 236
- 18.10 Disorders of the Canalis Analis: Hemorrhoidal Disease, Anal Abscesses, and Anal Fistulas 238
- 18.11 Rectal Carcinoma 240
- 18.12 Hepar:
 - Position and Relationship to Adjacent Organs 242
- 18.13 Peritoneal Relationships and Shape 244
- 18.14 Segmentation and Histology 246
- 18.15 Vesica Biliaris and Ductus Biliares:
 - Location and Relationships to Adjacent Organs 248
- 18.16 Extrahepatic Ductus Biliares and Ductus Pancreatici 250
- 18.17 Pancreas 252
- 18.18 Splen 254
- 18.19 Branches of the Truncus Coeliacus:
 - Arteries Supplying the Gaster, Hepar, and Vesica Biliaris 256
- 18.20 Arteries Supplying the Pancreas, Duodenum, and Splen. 258

- 18.21 Branches of the Arteria Mesenterica Superior:
 - Arteries Supplying the Pancreas, Intestinum Tenue, and Intestinum Crassum 260
- 18.22 Branches of the Arteria Mesenterica Inferior:
 - Arteries Supplying the Intestinum Crassum 262
- 18.23 Supply to the Rectum 264
- 18.24 Vena Portae Hepatis: Venous Drainage of the Gaster, Duodenum, Pancreas, and Splen. 266
- 18.25 Venae Mesentericae Superior and Inferior:
 - Venous Drainage of the Intestina Tenue and Crassum 268
- 18.26 Branches of the Vena Mesenterica Inferior:
 - Venous Drainage of the Rectum 270
- 18.27 Lymphatic Drainage of the Gaster, Splen, Pancreas, Duodenum, and Hepar 272
- 18.28 Lymphatic Drainage of the Intestina Tenue and Crassum . 274
- 18.29 Autonomic Innervation of the Hepar, Vesica Biliaris, Gaster, Duodenum, Pancreas, and Splen 276
- 18.30 Autonomic Innervation of the Intestinum:
 - Distribution of the Plexus Mesentericus Superior. 278
- 18.31 Distribution of the Plexus Mesentericus Inferior and Plexus Hypogastricus Inferior 280

19 Organs of the Urinary System and their Neurovasculature

- 19.1 Overview of the Urinary Organs; The Renes in situ 282
- 19.2 Renes:
 - Location, Shape, and Structure 284
- 19.3 Architecture and Microstructure 286
- 19.4 Pelvis Renalis and Urinary Transport 288
- 19.5 Glandulae Suprarenales 290
- 19.6 Ureteres in situ 292
- 19.7 Vesica Urinaria in situ 294
- 19.8 Vesica Urinaria, Cervix Vesicae, and Urethra:
 - Wall Structure and Function. 296
- 19.9 Functional Anatomy of Urinary Continence 298
- 19.10 Urethra 300
- 19.11 Arteries and Veins of the Renes and Glandulae Suprarenales:
 - Overview 302
 - Variants 304
- 19.12 Lymphatic Drainage of the Renes, Glandulae Suprarenales, Ureter, and Vesica Urinaria. 306
- 19.14 Autonomic Innervation of the Urinary Organs and Glandulae Suprarenales 308

20 Organs of the Genital System and their Neurovasculature

- 20.1 Overview of the Genital Tract 310
- 20.2 Female Internal Genitalia:
 - Overview 312
- 20.3 Topographical Anatomy and Peritoneal Relationships; Shape and Structure 314
- 20.4 Wall Structure and Function of the Uterus 316
- 20.5 Positions of the Uterus and Vagina 318

Neurovascular Supply to the Organs: A Schematic Approach

| | | |
|-------|---|-----|
| 20.6 | Epithelial Regions of the Uterus | 320 |
| 20.7 | Cytologic Smear, Conization; Cervical Carcinoma | 322 |
| 20.8 | Female Internal Genitalia: Ovary and Follicular Maturation | 324 |
| 20.9 | Pregnancy and Childbirth | 326 |
| 20.10 | Male Genitalia: Accessory Sex Glands | 328 |
| 20.11 | Prostate Tumors: Prostatic Carcinoma, Prostatic Hyperplasia; Cancer Screening | 330 |
| 20.12 | Male Genitalia: Scrotum, Testis, and Epididymis | 332 |
| 20.13 | Seminiferous Structures and Ejaculate | 334 |
| 20.14 | Branches of the Arteria Iliaca Interna: Overview of Arteries Supplying the Pelvic Organs and Pelvic Wall | 336 |
| 20.15 | Vascularization of the Male Pelvic Organs | 338 |
| 20.16 | Vascularization of the Female Pelvic Organs | 340 |
| 20.17 | Vascularization of the Female Internal Genitalia and Vesica Urinaria | 342 |
| 20.18 | Lymphatic Drainage of the Male and Female Genitalia | 344 |
| 20.19 | Autonomic Innervation of the Male Genitalia | 346 |
| 20.20 | Autonomic Innervation of the Female Genitalia | 348 |

| | | |
|-------|--|-----|
| 22.1 | Thymus | 400 |
| 22.2 | Oesophagus | 401 |
| 22.3 | Heart | 402 |
| 22.4 | Pericardium | 403 |
| 22.5 | Lung and Trachea | 404 |
| 22.6 | Diaphragm | 405 |
| 22.7 | Hepar, Vesica Biliaris, and Splen | 406 |
| 22.8 | Gaster | 407 |
| 22.9 | Duodenum and Pancreas | 408 |
| 22.10 | Jejunum and Ileum | 409 |
| 22.11 | Caecum, Appendix Vermiformis, Colon Ascendens and Transversum | 410 |
| 22.12 | Colon Descendens and Colon Sigmoides | 411 |
| 22.13 | Rectum | 412 |
| 22.14 | Kidney, Ureter, and Glandula Suprarenalis | 413 |
| 22.15 | Vesica Urinaria, Prostata, and Glandula Vesiculosa | 414 |
| 22.16 | Testis, Epididymis, and Ductus Deferens | 415 |
| 22.17 | Uterus, Tuba Uterina, and Vagina | 416 |
| 22.18 | Tuba Uterina and Ovarium | 417 |

21 Topographical Anatomy

| | | |
|-------|--|-----|
| 21.1 | Surface Anatomy, Topographic Regions, and Palpable Bony Landmarks | 350 |
| 21.2 | Location of the Abdominal and Pelvic Organs and their Projection onto the Trunk Wall | 352 |
| 21.3 | Topography of the Opened Cavitas Peritonealis (Supracolic and Infracolic Part) | 354 |
| 21.4 | Drainage Spaces and Recesses within the Cavitas Peritonealis | 356 |
| 21.5 | Overview of the Mesenteria | 358 |
| 21.6 | Topography of the Bursa Omentalis | 360 |
| 21.7 | Topography of the Upper Abdominal Organs: Hepar, Vesica Biliaris, Duodenum, and Pancreas | 362 |
| 21.8 | Gaster and Splen | 364 |
| 21.9 | Cross-Sectional Anatomy of the Upper Abdominal Organs | 366 |
| 21.10 | Topography of the Intestina Tenue and Crassum | 368 |
| 21.11 | Radiography of the Intestina Tenue and Crassum | 370 |
| 21.12 | Topography of the Rectum | 372 |
| 21.13 | Retroperitoneum: Overview and Divisions | 374 |
| 21.14 | Peritoneal Relationships | 376 |
| 21.15 | Organs of the Retroperitoneum | 378 |
| 21.16 | Location of the Kidneys | 380 |
| 21.17 | Peritoneal Relationships in the Anterior Abdominal Wall | 382 |
| 21.18 | Peritoneal Relationships in the Pelvis Minor | 384 |
| 21.19 | Topography of Pelvic Connective Tissue, Levels of the Cavitas Pelvis, and the Diaphragma Pelvis | 386 |
| 21.20 | Suspensory Apparatus of the Uterus | 388 |
| 21.21 | Female Pelvis in situ | 390 |
| 21.22 | Male Pelvis in situ | 392 |
| 21.23 | Cross-Sectional Anatomy of the Female Pelvis | 394 |
| 21.24 | Cross-Sectional Anatomy of the Male Pelvis | 396 |

Organ Fact Sheets

| | | |
|-------|---|-----|
| 23.1 | Thymus | 420 |
| 23.2 | Pericardium | 421 |
| 23.3 | Cor (Heart) | 422 |
| 23.4 | Trachea, Bronchi, and Lungs. | 424 |
| 23.5 | Oesophagus | 426 |
| 23.6 | Gaster (Stomach) | 427 |
| 23.7 | Intestinum Tenue: | |
| | Duodenum | 428 |
| 23.8 | Jejunum and Ileum | 429 |
| 23.9 | Intestinum Crassum: | |
| | Caecum with Appendix Vermiformis and Colon | 430 |
| 23.10 | Rectum | 431 |
| 23.11 | Hepar (Liver) | 432 |
| 23.12 | Vesica Biliaris (Gallbladder) and Bile Ducts | 433 |
| 23.13 | Pancreas | 434 |
| 23.14 | Splen (Spleen) | 435 |
| 23.15 | Glandulae Suprarenales (Suprarenal or Adrenal Glands) | 436 |
| 23.16 | Renes (Kidneys) | 437 |
| 23.17 | Ureter | 438 |
| 23.18 | Vesica Urinaria (Urinary Bladder) | 439 |
| 23.19 | Urethra | 440 |
| 23.20 | Vagina | 441 |
| 23.21 | Uterus and Tubae Uterinae (Uterine Tubes) | 442 |
| 23.22 | Prostata and Glandula Vesiculosa (Seminal Vesicle) | 444 |
| 23.23 | Epididymis and Ductus Deferens | 445 |
| 23.24 | Testis | 446 |
| 23.25 | Ovarium | 447 |

Appendix

| | |
|-------------------|-----|
| References | 451 |
| Index | 453 |

Foreword

Each of the authors of the single volume *Thieme Atlas of Anatomy* was impressed with the extraordinary detail, accuracy, and beauty of the illustrations that were created for the Thieme three-volume series of anatomy atlases. We felt these images were one of the most significant additions to anatomic education in the past 50 years. The effective pedagogical approach of this series, with two-page learning units that combined the outstanding illustrations and captions that emphasized the functional and clinical significance of structures, coupled with the numerous tables summarizing key information, was unique. We also felt that the overall organization of each region, with structures presented first systemically—musculoskeletal, vascular, and nervous—and then topographically, supported classroom learning and active dissection in the laboratory.

This series combines the best of a clinically oriented text and an atlas. Its detail and pedagogical presentation make it a complete support for classroom and laboratory instruction and a reference for life in all the

medical, dental and allied health fields. Each of the volumes—*General Anatomy and Musculoskeletal System*, *Internal Organs*, and *Head, Neck, and Neuroanatomy*—can also be used as a stand-alone text/atlas for an in-depth study of systems often involved in the allied health/medical specialty fields.

We were delighted when Thieme asked us to work with them to create a single-volume atlas from this groundbreaking series, and we owe a great debt to the authors and illustrators of this series in as much as their materials and vision formed the general framework for the single volume *Thieme Atlas of Anatomy*.

We thank the authors and illustrators for this very special contribution to the teaching of anatomy and recommend it for thorough mastery of anatomy and its clinically functional importance in all fields of health care-related specialties.

Lawrence M. Ross, Brian R. MacPherson, and Anne M. Gilroy

Preface to the Second Edition

Gain new insights with the help of the *Thieme Atlas of Anatomy*!

In recent years, the combination of theoretical and clinical knowledge has taken on an increasingly important role in medical education and training. The *Thieme Atlas of Anatomy* has always been cognizant of these changes by including references in legends, adding select illustrations and creating new units wholly devoted to a particular clinically relevant topic.

The close relationship between classic and clinical anatomy does not only manifest itself in medical students gaining experience in clinical work early on in their studies. On the contrary, research in clinical anatomy often influences classic anatomy and in turn becomes a part of medical education.

One such example is the findings of decades-long clinical research conducted by colleagues in the Urology Clinic of the University of Leipzig. Among other topics, the urologists in Leipzig have researched how to protect structures important for urine continence during pelvic surgeries, such as radical prostatectomies. This procedure, despite preserving the sphincter and its innervation, often results in postoperative urinary incontinence. The team, led by Professor Jens-Uwe Stolzenburg and Dr. Thilo Schwalenberg, searched for the causes of this phenomenon and discovered that, as a result of surgery to remove the prostate, the location of the sphincter may change or musculo-fibrous structures that

anchor the neck of the bladder and the urethral sphincter to the pelvic floor, may get damaged. The team's research has shown that preserving these musculo-fibrous structures during prostatectomy significantly reduces the risk of postoperative urinary incontinence.

The colleagues in Leipzig deserve great credit for recognizing these relationships and for discovering that significantly more structures than "only" the sphincter and its innervation are involved in micturition and continence. It is thanks to the team's research in clinical anatomy that we today have a better understanding of the complex continence mechanism, which we are now able to share with medical students. This volume about the internal organs has been revised to include these latest findings.

We would like to take this opportunity to explicitly thank our readers for their feedback and to encourage them to keep sending us their comments and remarks. The *Thieme Atlas of Anatomy* will continue to give you the support you need!

We wish you success studying with the *Thieme Atlas of Anatomy*!

*Michael Schuenke, Erik Schulte, Udo Schumacher,
Markus Voll, and Karl Wesker
Kiel, Mainz, Hamburg, Munich, and Berlin*

Preface to the First Edition

When Thieme started planning this atlas, they sought the opinions of students and instructors in both the United States and Europe on what constituted an “ideal” atlas of anatomy—ideal to learn from, to master extensive amounts of information while on a busy class schedule, and, in the process, to acquire sound, up-to-date knowledge. The result of our work in response to what Thieme learned is this atlas. The *Thieme Atlas of Anatomy*, unlike most other atlases, is a comprehensive educational tool that combines illustrations with explanatory text and summary tables, introducing clinical applications throughout, and presenting anatomic concepts in a step-by-step sequence that includes system-by-system and topographical views.

Because the *Thieme Atlas of Anatomy* is based on a fresh approach to the underlying subject matter, it was necessary to create an entirely new set of illustrations for it—a task that took eight years. Our goal was to pro-

vide illustrations that would compellingly demonstrate anatomic relations and concepts, revealing the underlying simplicity of human anatomy without sacrificing detail or aesthetics.

With the *Thieme Atlas of Anatomy*, it was our intention to create an atlas that would guide students in their initial study of anatomy, stimulate their enthusiasm for this intriguing and vitally important subject, and provide a reliable reference for experienced students and professionals alike.

“If you want to attain the possible, you must attempt the impossible”
(Rabindranath Tagore).

*Michael Schuenke, Erik Schulte, Udo Schumacher,
Markus Voll, and Karl Wesker*

A Note on the Use of Latin Terminology

To introduce the Latin nomenclature into an English textbook is a delicate task, particularly because many Latin loanwords have passed into general use. Some loanwords are so common that fluency of the text would be disturbed if they were to be translated back into Latin. These Latin loanwords have typically undergone several adaptations before becoming part of the English language. A term such as *sympathetic trunk* (lat. *truncus sympaticus*) has undergone morphological adaptation (through the loss of masculine suffix *-us*), orthographical adaptation (through the substitution of a 'Germanic' *k* for a Latin *c*), and phonological adaptation (*th* and *e* instead of *t* and *i*). In addition, the word order has been reversed. The Latin term *sympaticus* is in fact borrowed from the late Greek word *sympathetikos* (from *sympathes* "having a fellow feeling, affected by like feelings"), thereby illustrating that terms move between languages when cultures meet.

Other anatomical terms are so colloquial (e.g., *hand*), that a Latin term (e.g., *manus*) would be inappropriate to use at all occasions. Clearly, the text would easily become unreadable if a strict translation of all English terms into Latin were imposed.

As a result, Latin has been used as long as it does not disrupt the flow of the text and whenever possible in figures and tables. In some cases, dual terminology has been used, with either the English or Latin word in parenthesis. As much as possible, the terminology of *Terminologia Anatomica* (1998) has been followed.

Hugo Zeberg, M.D., Ph.D.
Lecturer
Karolinska Institutet

Acknowledgments

First, we wish to thank our families. This atlas is dedicated to them.

We also thank Prof. Reinhard Gossrau, M.D., for his critical comments and suggestions. We are grateful to several colleagues who rendered valuable help in proofreading: Mrs. Gabriele Schünke, Jakob Fay, M.D., Ms. Claudia Dücker, Ms. Simin Rassouli, Ms. Heinke Teichmann, and Ms. Sylvia Zilles. We are also grateful to Dr. Julia Jürns-Kuhnke for helping with the figure labels.

We extend special thanks to Stephanie Gay and Bert Sender, who prepared the layouts. Their ability to arrange the text and illustrations on facing pages for maximum clarity has contributed greatly to the quality of the atlas.

We particularly acknowledge the efforts of those who handled this project on the publishing side: Jürgen Lüthje, M.D., Ph.D., executive editor at Thieme Medical Publishers, has “made the impossible possible.” He not only reconciled the wishes of the authors and artists with the demands of reality but also managed to keep a team of five people working together for years on a project whose goal was known to us from the beginning but whose full dimensions we only came to appreciate over time. He is deserving of our most sincere and heartfelt thanks.

Sabine Bartl, developmental editor, became a touchstone for the authors in the best sense of the word. She was able to determine whether a beginning student, and thus one who is not (yet) a professional, could

clearly appreciate the logic of the presentation. The authors are indebted to her.

We are grateful to Antje Bühl, who was there from the beginning as project assistant, working “behind the scenes” on numerous tasks such as repeated proofreading and helping to arrange the figure labels.

We owe a great debt of thanks to Martin Spencker, managing director of Educational Publications at Thieme, especially to his ability to make quick and unconventional decisions when dealing with problems and uncertainties. His openness to all the concerns of the authors and artists established conditions for a cooperative partnership.

Without exception, our collaboration with the entire staff at Thieme Medical Publishers was consistently pleasant and cordial. Unfortunately, we do not have room to list everyone who helped in the publication of the *Atlas*, and we must limit our acknowledgments to a few colleagues who made a particularly notable contribution: Rainer Zepf and Martin Waletzko for support in all technical matters; Susanne Tochtermann-Wenzel and Manfred Lehnert, representing all those who were involved in the production of the book; Almut Leopold for the index; Marie-Luise Kürschner and her team for creating the cover design; to Liesa Arendt, Birgit Carlsen, and Anne Döbler, representing all those who handled marketing, sales, and promotion.

The Authors

I thank my wife, Valerie, and son, Robert, for their love, support, and understanding. Nothing means more to me than the two of you.

As Consulting Editor I was asked to review the English translation of *Thieme Atlas of Anatomy: Internal Organs*, Second Edition. My work involved reviewing and editing the translation and nomenclature conversion of the German text to currently used English terms. In addition, some minor changes in presentation were made to reflect commonly accepted approaches in North American educational programs. This task was facilitated by the clear organization of the original text, the exceptional work of the translators, and the previous work of the Consulting Editors of the first edition. Throughout this process I have tried to remain faithful to the intentions and insights of the authors and illustrators, whom I thank for this outstanding revision.

It has been a great honor to act as a consulting editor, with responsibility for the Latin nomenclature, for *Thieme Atlas of Anatomy: Internal Organs*, Second Edition. There were several people from whom I received a great deal of assistance and guidance, and must express my gratitude towards. I would wish to thank Prof. Eugen Flamm, M.D. for having given me the opportunity to study clinical neuroanatomy and for sharing his great knowledge in anatomy. Regarding the discussion of nomenclature, I would wish to thank my mentor Prof. Peter Århem, Ph.D., my father Lennart Zeberg, M.D., and Prof. Jonas Broman, Ph.D. In addition, I would also like to express my gratitude to Prof. Björn Meister, M.D., Ph.D., and Prof. Kaj Fried, Ph.D.

I would also like to thank the entire team at Thieme Medical Publishers who worked on this edition. In particular I would like to give special thanks to Anne M. Sydor, Ph.D., Editorial Director for Educational Products, for inviting me to work on this atlas and for her continued support; and to Huvie Weinreich, Editorial Assistant, and Judith Tomat, Managing Editor and Translator, for their support and help throughout the process of completing this atlas.

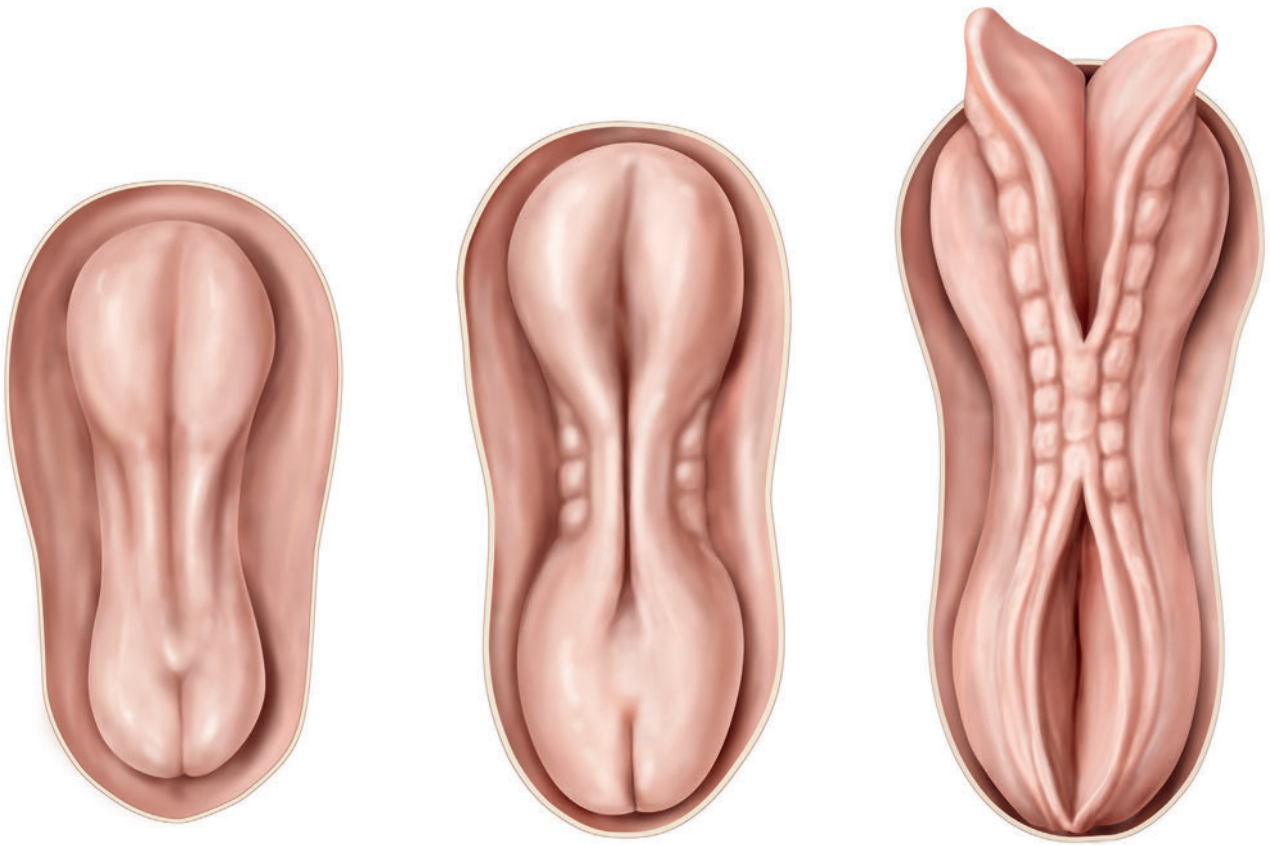
I also thank Brain R. MacPherson, Ph.D., Professor of Anatomy and Neurobiology at the University of Kentucky, for his comments and suggestions concerning this project.

Wayne A. Cass

Moreover, I am deeply grateful to the staff at Thieme Medical Publishers that I have been in close contact with, in particular, the editorial director Anne Sydor, Ph.D., managing editor Judith Tomat, marketing agent David Towle.

I would also like to acknowledge the Federative International Programme for Anatomical Terminology (FIPAT) for their work towards a standard nomenclature in the field of anatomy.

Hugo Zeberg



Structure and Development of Organ Systems

| | | |
|---|------------------------------------|----|
| 1 | Body Cavities | 2 |
| 2 | Cardiovascular System | 10 |
| 3 | Respiratory System | 22 |
| 4 | Digestive System | 28 |
| 5 | Urinary System | 40 |
| 6 | Genital System | 46 |
| 7 | Lymphatic System | 56 |
| 8 | Endocrine System | 60 |
| 9 | Autonomic Nervous System | 64 |

1.1 Definitions, Overview, and Evolution of Body Cavities

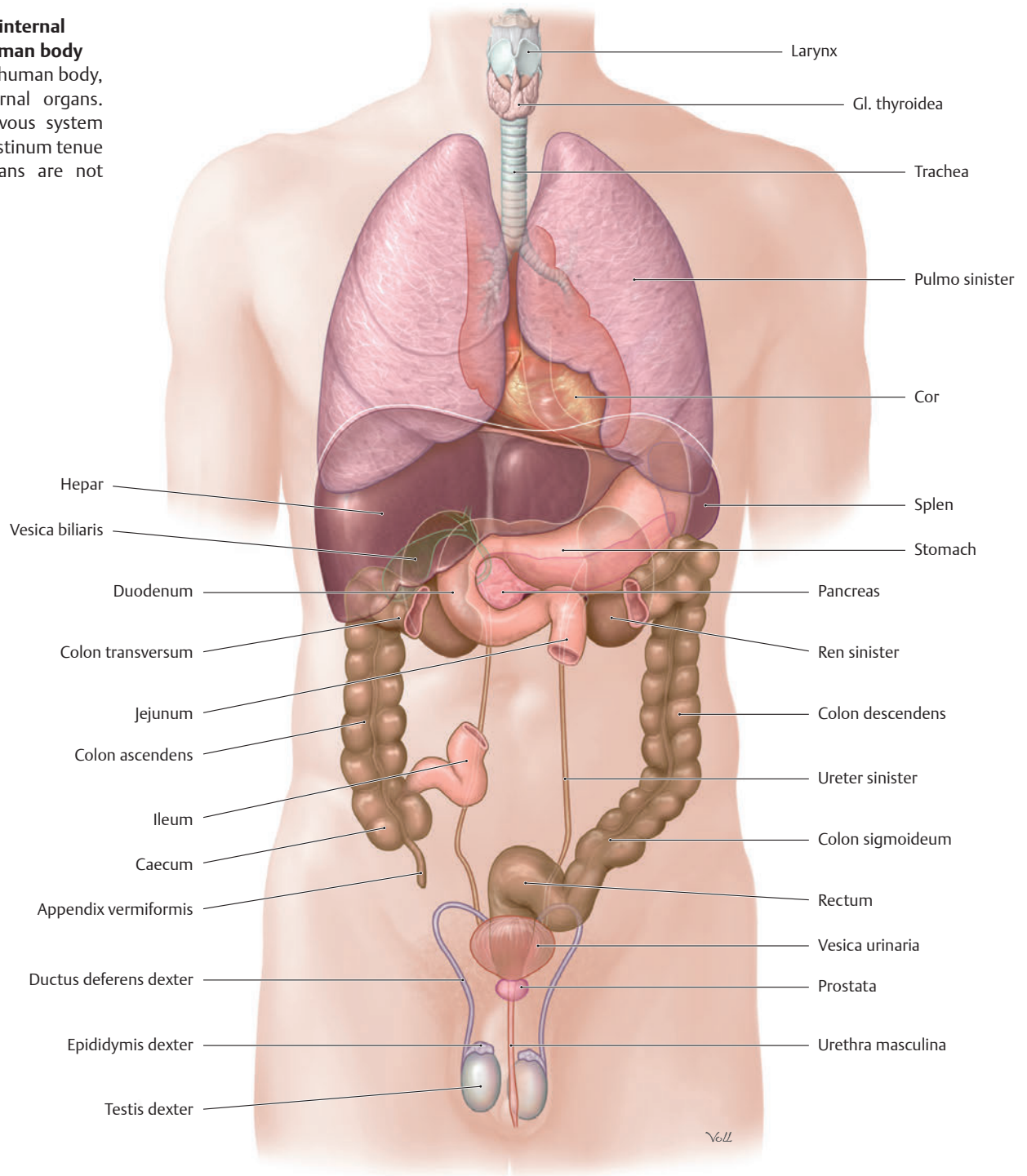
Definitions

The human body, similar to all higher organisms, is organized into a hierarchy of different levels:

- A **cell** is the smallest unit of life, that in principle can survive on its own.
- A **tissue** consists primarily of cells from the same origin, and the extracellular matrix they form. A tissue is an ensemble of cells, organized to do a specific job.
- An **organ** is a structural unit composed of different tissues. Thus, it combines the functions of the various tissue components.
- An **organ system** is made up of organs that function together to perform a specific function. For example, the digestive organs make up the *digestive system*. For the most part, the individual organs are related to each other morphologically.
- An **organism** is composed of several organ systems.

A Overview of the internal organs of the human body

Anterior view of the human body, displaying the internal organs. For clarity, the nervous system and most of the intestinum tenue and endocrine organs are not shown.



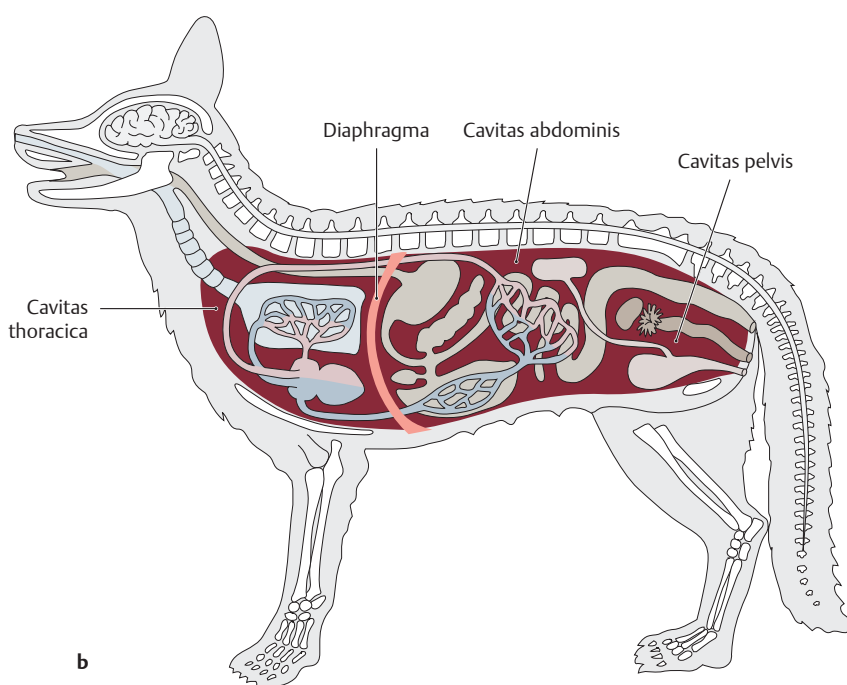
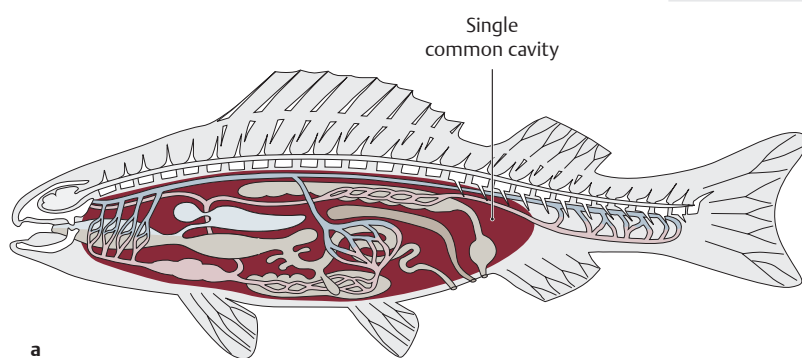
B Overview of organ systems

Since, by definition, every structural unit composed of different tissues is referred to as an organ (according to this definition, every muscle is an organ), the term is commonly used for structures in the cranium, neck, and body cavities. The organs situated inside the body cavities are referred to as internal organs or viscera. This atlas is a study aid for learning gross anatomy. Thus, the individual organs are discussed with respect to their topography. However, since groups of individual organs form morphological and functional systems, which due to evolutionary processes don't conform to topographical anatomy, those organ systems along with their embryology will be discussed first. This overview will aid in understanding the location, shape and function of the internal organs in the developing organism.

Note: Peripheral nerves, bone marrow, and blood are usually not referred to as "organs." For the sake of completeness, they will also be discussed since they are part of whole organ systems.

* Organs that are highlighted in italics are located in the neck or cranium and thus will not be discussed here.

| System | Organs* |
|-------------------------|---|
| Systema digestorium | <i>Cavitas oris with dentes and gll. salivariae</i> , pharynx, oesophagus, stomach (gaster), intestinum tenue, intestinum crassum, rectum, pancreas, liver (hepar), and vesica fellea |
| Systema respiratorium | <i>Cavitas nasi and sinus paranasales</i> , larynx, trachea, pulmones |
| Systema urinarium | Kidneys (renes), ureteres, vesica urinaria, urethra |
| Systema genitale | ♀ Uterus, tubae uterinae (salpinges), ovarium, vagina, gll. vestibulares majores ♂ Testes, epididymis, ductus deferens, vesiculae seminales, prostata, gl. bulbourethralis |
| Systema cardiovasculare | Heart (cor), vessels, blood, and <i>medulla ossium rubra</i> |
| Systema lymphoideum | <i>Medulla ossium, tonsillae</i> , thymus, splen, nodi lymphoidei, ductus thoracicus |
| Systema endocrinum | <i>Gl. thyroidea, gll. parathyroideae</i> , gll. suprarenales (adrenal), paraganglia, pancreas (islet cells), ovaria, testes, <i>hypophysis, hypothalamus</i> |
| Systema nervosum | <i>Encephalon, medulla spinalis</i> , systema nervosum periphericum (with <i>somatic</i> and autonomic components) |



C Evolution of body cavities

While in fish (a) all internal organs are situated in a single common body cavity, in mammals (b), the diaphragm separates the cavitas thoracica from the cavitas abdominis. Due to shared evolutionary history, the structures of these two body cavities are basically identical. The different anatomical terms used for similar structures (e.g., pleura – peritoneum) are functionally meaningless. In mammals, there is no physical structure that separates the cavitas abdominis from the cavitas pelvis. They form a continuous space that in terms of its topographical anatomy is divided only by the superior border of the bony pelvis. The anatomical unit of the cavitates abdominis and pelvis is of clinical significance as there are no anatomical barriers to restrict the spread of inflammation or tumors between these two compartments. The diaphragm acts as a barrier to stop tumors or inflammation from spreading from the cavitas abdominis to the cavitas thoracica and vice versa.

1.2 Organogenesis and the Development of Body Cavities

A Differentiation of the germ layers (after Christ and Wachtler)

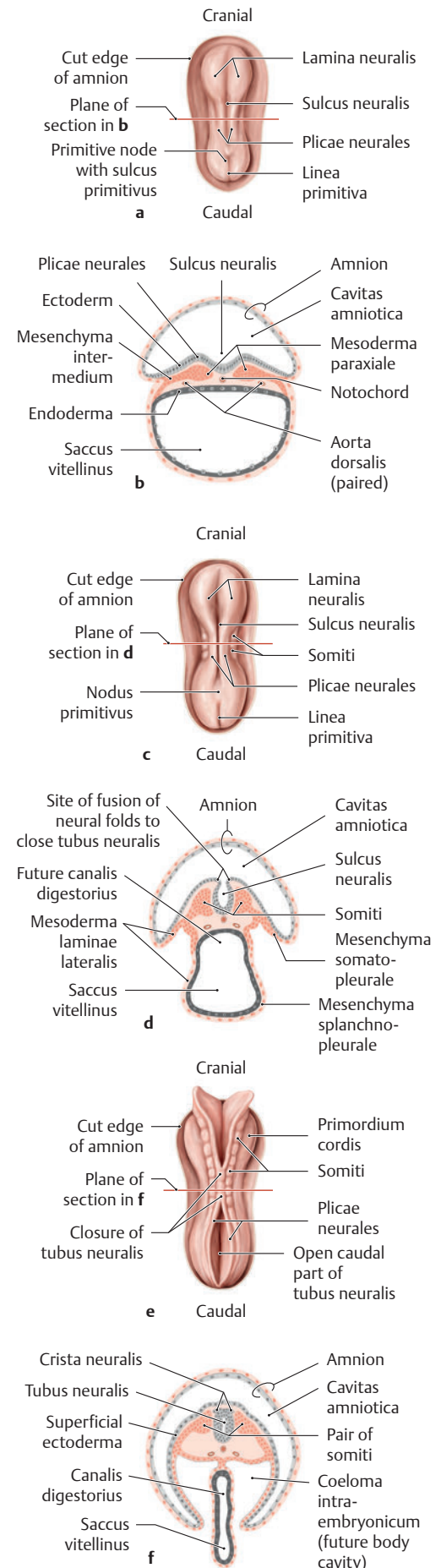
After the formation of the trilaminar discus embryonicus at the end of the third week (see B) the primordia (precursor cells destined to become a specific tissue or organ) of the different tissues and organs are arranged according to the body plan. In the subsequent embryonic period (weeks 4 to 8), the three germ layers (ectoderma, mesoderma, and endoderma) give rise to all major external and internal organs (organogenesis). At the same time, the trilaminar discus embryonicus begins to fold, resulting in major changes in body form and internal structure. By the end of the embryonic stage, the major features of the body are recognizable and the organs have moved into their eventual position within and outside of the body cavities.

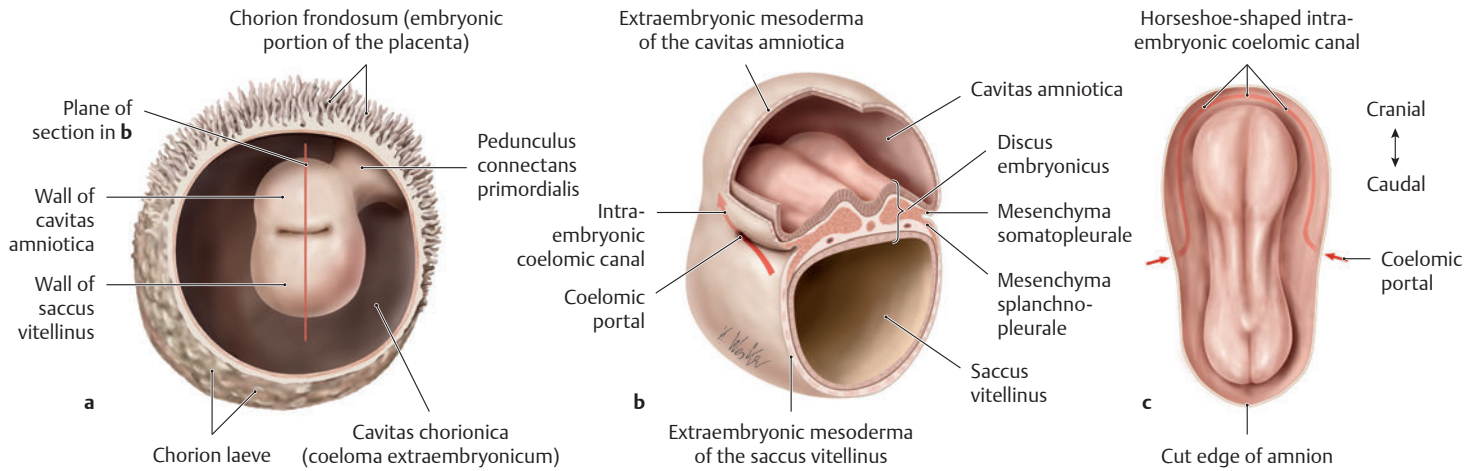
| | | | |
|-----------|------------------------------|--|---|
| Ectoderma | Tubus neuralis | Encephalon, retina, medulla spinalis | |
| | Crista neuralis | Crista neuralis cranialis | Ganglia sensoria and parasympathica, pars enterica systematis nervosi, thyrocyti C, textus muscularis levis, pigment cells, glomus caroticum, bone, cartilage, connective tissue, dentinum and cementum of the teeth, dermis, and tela subcutanea of the head |
| | | Crista neuralis truncalis | Ganglia sensoria and autonómica, gliocyti peripherici, medulla suprarenalis, melanocyti, intramural plexuses |
| | Surface ectoderma | Ectodermal placodesae | Adenohypophysis, ganglia sensoria nervorum cranialium, epithelium olfactorium, auris interna, lens |
| | | Enamelum of the teeth, epithelium cavitatis oris, gl. salivariae, cavitates nasi, sinus paranasales, lacrimal passages, porus acusticus externus, epidermis, hair, nails, cutaneous glands | |
| Mesoderma | Axial | Notochorda, prechordal mesoderma | Musculi externi bulbi oculi |
| | Paraxiale | | Columna vertebralis, costae, textus muscularis striatus, connective tissue, dermis and subcutis of the back and part of the head, smooth muscle, blood vessels |
| | Mesenchyma intermedium | | Renes (kidneys), gonada, renal and genital excretory ducts |
| | Meso-derma laminae lateralis | Visceral (mesenchyma splanchnopleurale) | Cor (heart), vasa sanguinea, textus muscularis levis, bowel wall, blood, cortex suprarenalis, tunica serosa pleurae visceralis |
| | | Parietal (mesenchyma somatopleurale) | Sternum, limbs (cartilage, bones, and ligaments), dermis and tela subcutanea of the anterolateral body wall, textus muscularis levis, connective tissue, tunica serosa pleurae parietalis |
| Endoderma | | Epithelium of the bowel, respiratory tract, digestive glands, gl. pharyngeales, tuba auditiva, cavitates tympani, vesica urinaria, thymus, gl. parathyroideae, gl. thyroidea | |

B Neurulation and Somitus Formation (after Sadler)

a, c, and e Dorsal views of the discus embryonicus after removal of the amnion;
b, d, and f Schematic cross-sections of the corresponding stages at the planes of section as marked in **a, c, and e**; Age is in postovulatory days.
 During neurulation (formation of the tubus neuralis from the lamina neuralis), the neurectoderma differentiates from the surface ectoderma, due to inductive influences from the notochorda, and the tubus neuralis and crista neuralis cells move inside the embryo.

- a and b** Discus embryonicus at 19 days: The sulcus neuralis is developing in the area of the lamina neuralis.
- c and d** Discus embryonicus at 20 days: In the mesoderma paraxiale, flanking both sides of the sulcus neuralis and notochorda, the first somiti have formed (they contain cellular material assigned to form the columna vertebralis, muscles, and subcutaneous tissue). Immediately lateral to the mesoderma paraxiale is the mesenchyma intermedium, and lateral to that is the mesoderma laminae lateralis. The sulcus neuralis is beginning to close to form the tubus neuralis and the embryo begins to fold.
- e and f** Discus embryonicus at 22 days: Eight pairs of somiti are seen flanking the partially closed tubus neuralis which is sinking below the ectoderma. In the mesoderma laminae lateralis, the coeloma intraembryonicum, or future body cavity, arises. It will later develop both a parietal and a visceral layer (somatopleure and splanchnopleure). On the side facing the coeloma, a mesothelial lining develops from the somato- and splanchnopleure. It later forms the tunicae serosae lining the cavitates pericardiaca, pleurali, and peritonealis. The tubus neuralis migrates deeper into the mesoderma, and the somiti differentiate into sclerotomus, myotomus, and dermatome.

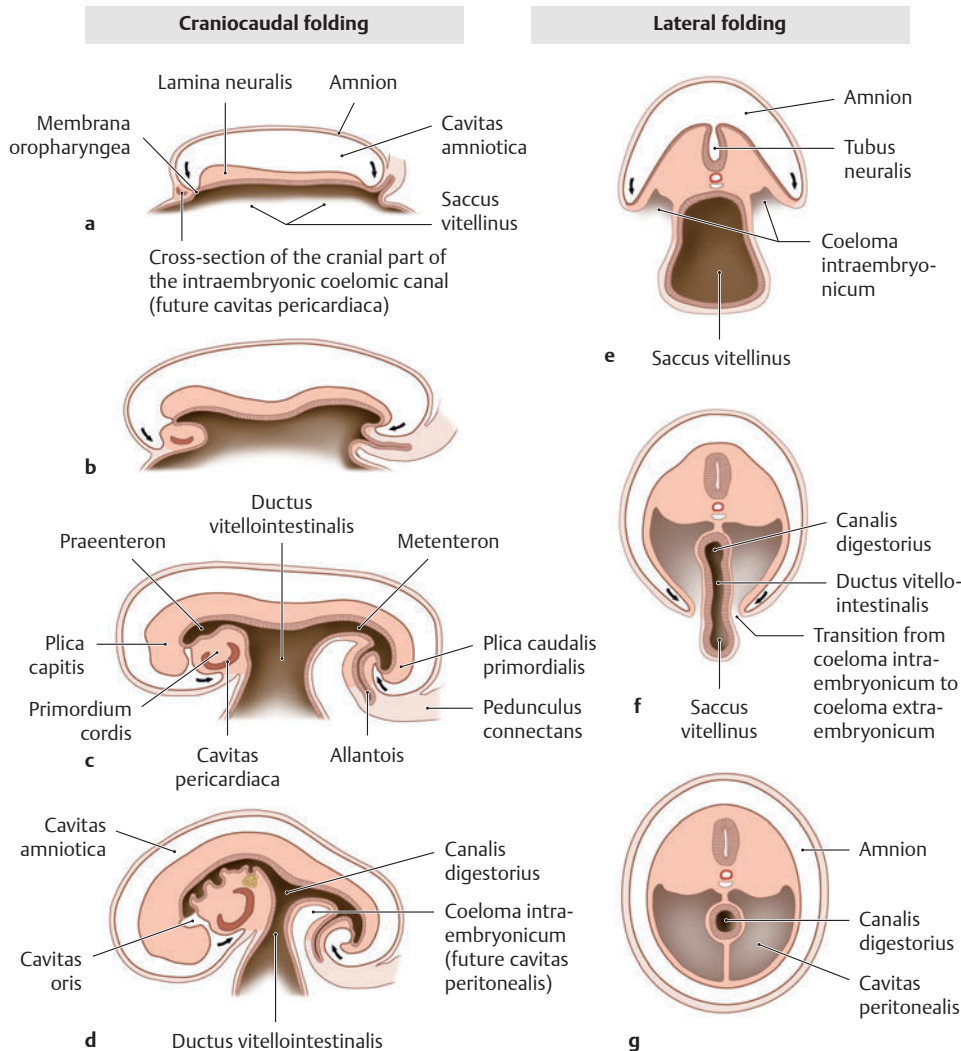




C Formation of the coeloma intraembryonicum (after Waldeyer)

a View into the chorionic cavity (coeloma extraembryonic); **b** Cut through the cavitas amniotica, discus embryonicus and saccus vitellinus (the cavitas chorionica has been removed); **c** View of the discus embryonicus (the intraembryonic coelomic canal has been highlighted in red). The eventual definitive serous cavities (cavitates pericardiaca, pleuralis, and peritonealis) arise from the coeloma intraembryonicum which begins to form in week 4 when intercellular clefts (not shown) appear in the mesoderma laminae lateralis (see **B**). The coeloma intraembryonicum divides the mesoderma laminae lateralis into parietal and visceral layers (*mesenchymata somatopleurale* and *splanchnopleurale*). At the edges of the discus embryonicus, the mesenchyma somatopleurale adjacent to the surface ectoderm is continuous with the extraembryonic mesoderma of the amnion. The mesenchyma splanchnopleu-

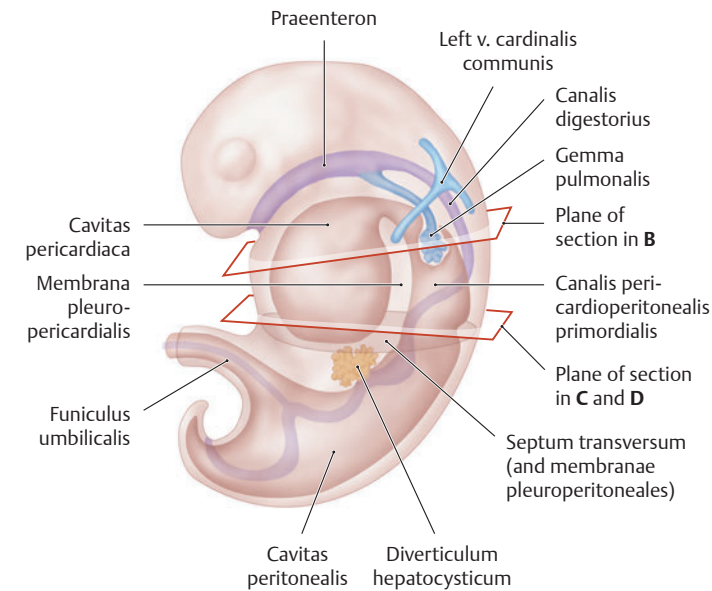
rale adjacent to the endoderma is continuous with the extraembryonic mesoderma of the saccus vitellinus. Thus, the coeloma intraembryonicum surrounds the opening of the saccus vitellinus like a ring (the *coelomic ring*). In the cranial part of the embryo, the coelomic ring closes off from the coeloma extraembryonicum (cavitas chorionica) and forms a horseshoe shaped intraembryonic *coelomic canal*, which is visible when viewed from above. The caudal coelomata intra and extraembryonicum (see **D**) continue to communicate with one another through the *coelomic portals*. Later, as a result of embryonic folding, the caudal coelomata intra- and extraembryonicum become separated from each other. During the course of embryonic development, the coeloma intraembryonicum compartmentalizes with the cavitas pericardiaca arising from the unpaired cranial part of the coeloma and the paired cavitates pleuralis and peritonealis arising from the lateral limbs of the coelom.



D Embryonic folding

a–d Midsagittal sections; **e–g** Frontal sections at the level of the saccus vitellinus. During folding the embryo is rapidly growing and it rises up from the surface of the original discus. The lamina neuralis grows rapidly and extends in both the cranial and caudal directions. As a result, the embryo curves upon itself (**a–d**). The formation of somiti causes a lateral expansion (lateral folding) of the embryo in the area above the saccus vitellinus (**e–g**). As a result, the intraembryonic coelomic canal shifts ventrally. Due to cranial folding (head fold), the cranial portion of the coeloma intraembryonicum moves ventral to the praenteron and broadens into the cavitas pericardiaca. The folding of the caudal tail moves the pedunculus connectans (the future funiculus umbilicalis) and the allantois to the ventral aspect of the embryo. While lateral folding occurs, the coeloma intraembryonicum progressively separates from the coelom extraembryonicum. These processes result in the junction between embryonic endoderma (primitive canalis digestorius) and saccus vitellinus (future pedunculus sacci vitellini) becoming increasingly narrow. At the same time, the left and right caudal parts of the coeloma intraembryonicum merge with one another forming a single large cavitas coelomica, which is the future cavitas peritonealis (for position of cavitates pleurales see p. 6).

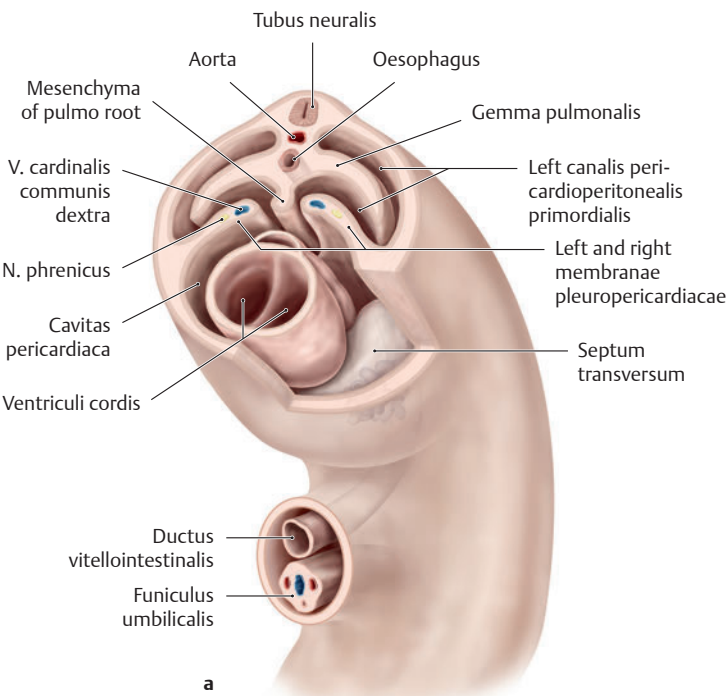
1.3 Compartmentalization of the Coeloma Intraembryonic



A Overview of the compartmentalization of the coeloma intraembryonic (after Drews)

Embryo at 4 weeks (viewed from left side).

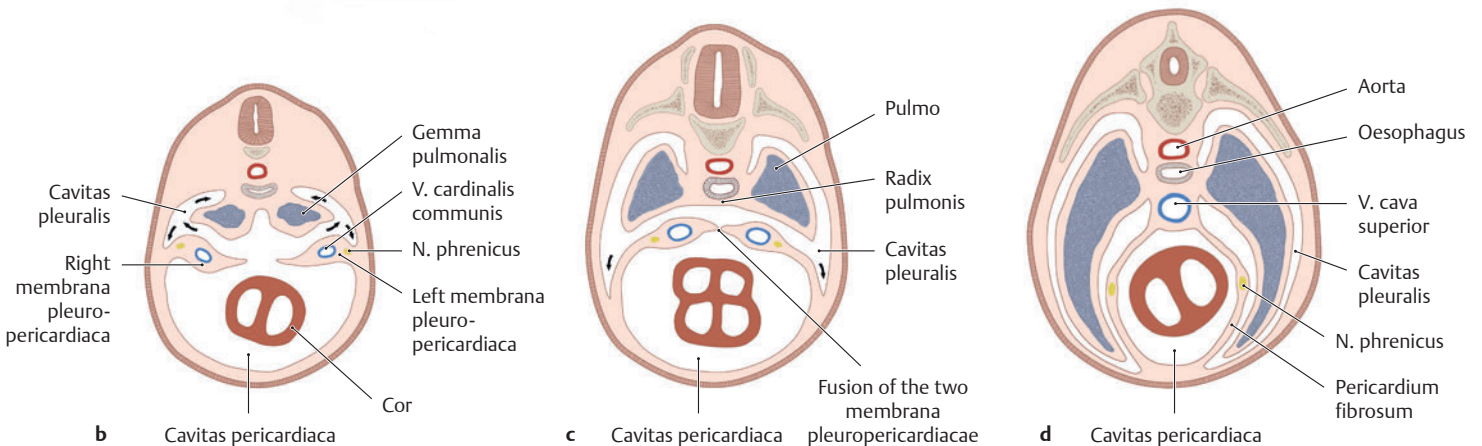
Due to cranial folding, the cranial portion of the coeloma intraembryonic moves ventral to the praenteron and broadens into the cavitas pericardiaca. The cavitas pericardiaca flanking the canalis digestorius (gut tube) communicates with the caudally located cavitas peritonealis through the canales pericardioperitoneales primordiales. The still unfolded parts of the future cavitas peritonealis initially open laterally into the cavitas chorionica. The gemmae pulmonales, which push from the canalis digestorius into the canales pericardioperitoneales, grow into the future paired cavitates pleurales. Through the formation of partitions, the pleural cavities separate from both the cavitas pericardiaca (membranae or plicae pleuropericardiacae) and the cavitas peritonealis (septum transversum and membranae or plicae pleuroperitoneales) (see B). In the frontal plane the plicae pleuropericardiacae originate on the cranio-lateral side of the two canales pericardioperitoneales primordiales in the area surrounding the vv. cardinales communes. They fuse with the mesoderma located ventral to the canalis digestorius (the future oesophagus). The plicae pleuroperitoneales develop in the caudolateral wall of the canales pericardioperitoneales and, together with the mesoesophagum dorsale and the septum transversum, form the future diaphragma (see D).

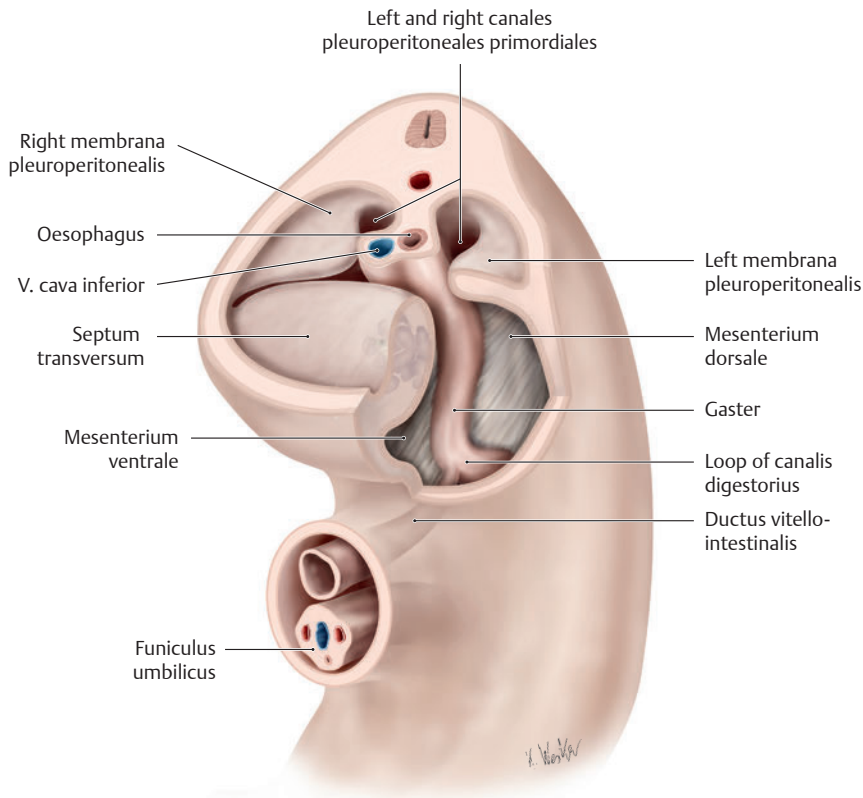


B Separation of the cavitas pericardiaca from the cavitates pleurales (after Sadler)

Embryo at 5 weeks. Frontal section at the level of the future cavitas pericardiaca; for plane of section see A.

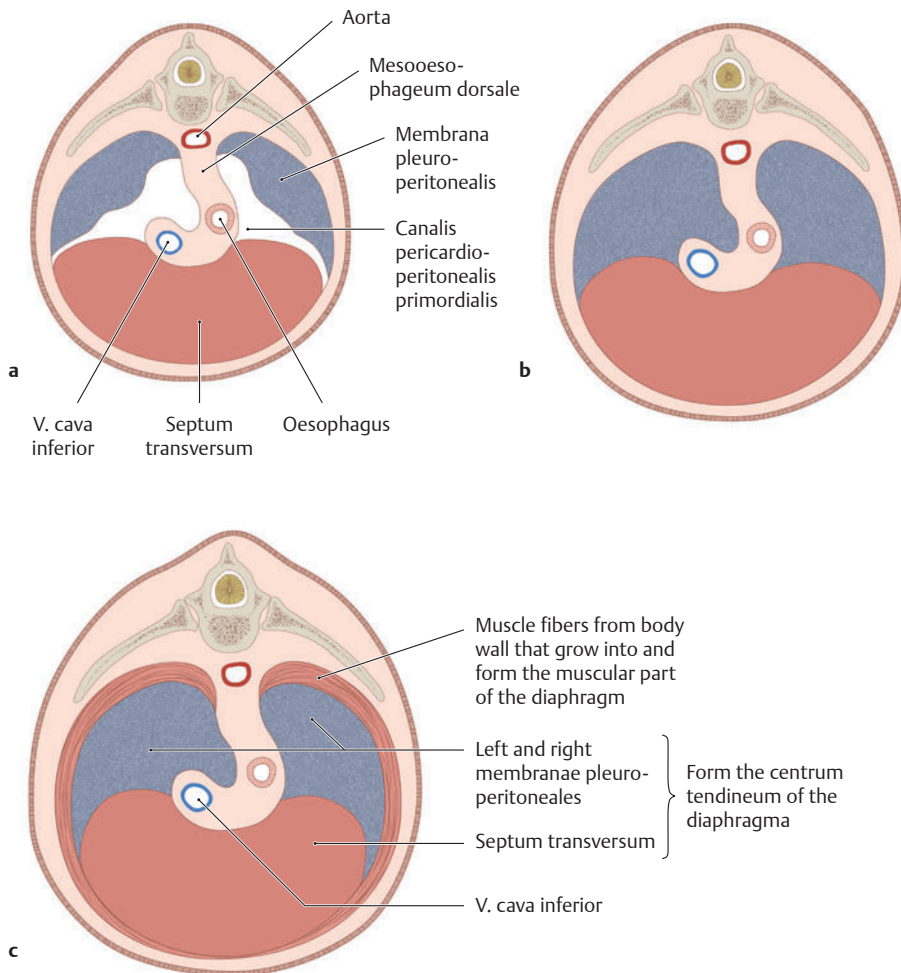
In the 5th week, at the junction between the unpaired cavitas pericardiaca and the two canales pericardioperitoneales, two thin mesoderm folds (plicae pleuropericardiacae), coming from the lateral direction, grow toward one another. They contain the trunks of the vv. cardinales communes and the nn. phrenici. The cavitates pleurales form as a result of the gemmae pulmonales growing into the canales pleuroperitoneales (see p. 26 development of the pulmones). In the course of further development, the cavitates pleurales further expand and become separate from the cavitas pericardiaca. The separation is complete once both of the plicae pleuropericardiacae have fused with the mesenchyma at the root of the lungs. The anterior vv. cardinales merge to form the v. cava superior; and the two plicae pleuropericardiacae give rise to the future pericardium fibrosum (see p. 14, development of the heart).





C Separation of the cavitates pleurales from the cavitas peritonealis
(after Sadler)

After the cavitates pleurales have separated from the cavitas pericardiaca, they are still temporarily connected to the cavitas peritonealis through the canales pericardioperitoneales. They become completely sealed off by the end of the 7th week with the development of the diaphragma, which is formed from several different structures (see D). Faulty closure of the canales pericardioperitoneales can lead to a *congenital hernia diaphragmatica* (e.g., Bochdalek hernia) allowing abdominal viscera to enter into the cavitates pleurales.



D Development of the diaphragma
(after Sadler)

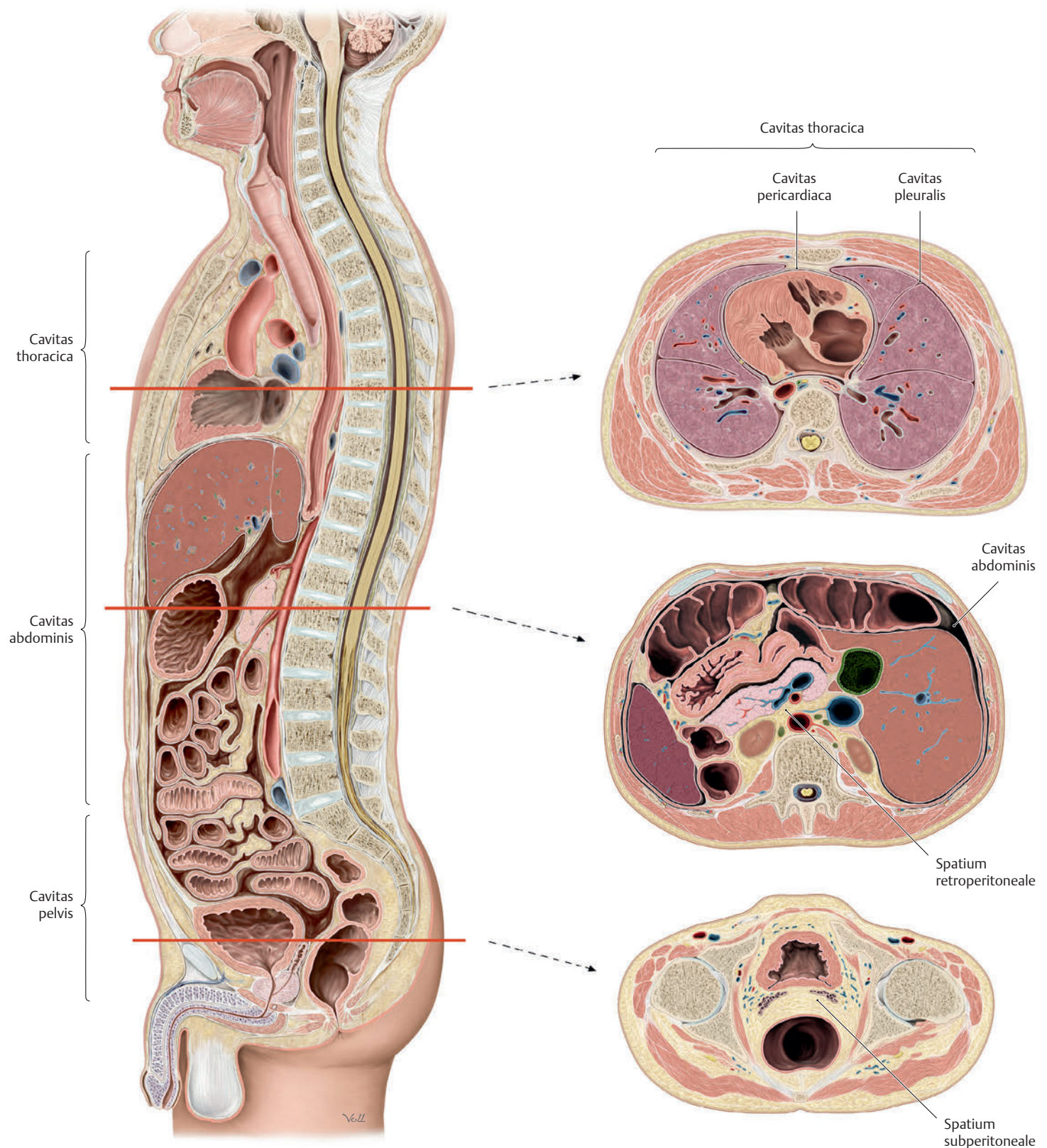
The diaphragma is derived from four different structures:

- the septum transversum
- the left and right plicae pleuroperitoneales
- the mesoesophageum dorsale
- body wall musculature

In the 4th week the septum transversum develops as a thick mesenchymal plate in the area between the cavitas pericardiaca and pedunculus sacci vitellini. In the 6th week, the septum transversum moves caudally (a). The hepar (liver) forms in the ventral mesenterium directly below it. During further development, the septum transversum fuses with both of the plicae pleuroperitoneales and forms the future *centrum tendineum* (b). The mesoesophageum dorsale and the adjacent body wall musculature give rise to the muscular part of the diaphragma (c).

Note: The nn. phrenici (C3, C4 and C5), located in the plicae pleuropericardiaca directly next to the trunks of the vv. cardiales communes, provide motor innervation to the diaphragma. The *textus muscularis striatus* of the diaphragma (from somiti), as well as the septum transversum, are originally from cervical regions. This explains why the nerve supply to the diaphragma (the nn. phrenici) comes from cervical medulla spinalis levels.

1.4 Organization and Architecture of Body Cavities

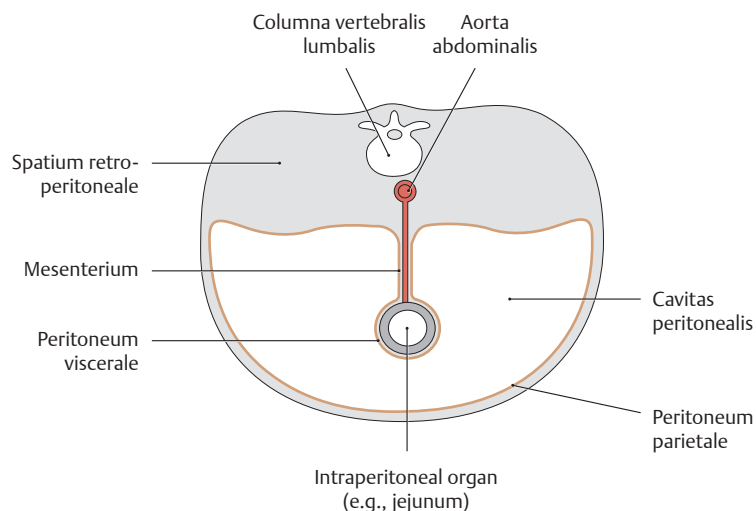


A Organization of the body cavities

Midsagittal section, viewed from the left side. Three large body cavities can be identified. From from the top down they are as follows

- Cavitas thoracica
- Cavitas abdominis
- Cavitas pelvis

These body cavities are completely surrounded by parts of the body wall. The majority of the walls consists of muscle and connective tissue. In addition, the thorax is surrounded by costae, and the pelvis by the ossa coxae. At its upper end, the connective tissue space of the cavitas thoracica is continuous with the connective tissue space of the neck. The diaphragma pelvis muscles close off the apertura pelvis inferior. Depending on their location in one of the three cavities, organs are referred to as thoracic, abdominal or pelvic organs (see C).



B Structure of the body cavities

Highly schematic cross-section of a human body; superior view. Every body cavity can be divided into two differently structured spaces:

- A **hollow space**: A smooth, moist epithelial layer, the serous membrane or tunica serosa, lines the inner wall of the cavity and the adjacent outer wall of the organs. The portion of the tunica serosa that covers the organ is called the *lamina visceralis* (viscera refers to internal organ). The portion lining the walls of the cavity is called the *lamina parietalis* (parietal refers to wall). The organs located in the cavity are movable. They are attached to the connective tissue space (see below) by a connective tissue bridge covered by a serous membrane (a mesenterium).
- A **connective tissue space** within which run the pathways leading to and from the organ. Organs situated in these spaces are surrounded by connective tissue and are more or less immovable.

While this general structure applies to all three body cavities, the terms for the individual regions vary (see C):

- In the **thorax**, most of the connective tissue is located in the central compartment of the cavitas thoracica, the mediastinum, in which the cavitas pericardiaca (a hollow space lined with a serous membrane) is embedded. The cavitates pleurales are located lateral to the mediastinum.

- In the **abdomen**, the connective tissue is situated behind the cavitas peritonealis in the spatium retroperitoneale (an extraperitoneal space).
- In the **pelvis**, the connective tissue is situated both behind and below the cavitas peritonealis in the spatia retroperitoneale and subperitoneale (spatia extraperitonealia).

Correspondingly, all organs in the thorax, abdomen and pelvis can be organized according to their location in the connective tissue space or in one of the serous-membrane lined cavities (see C).

Note: While the partition between the cavitates thoracica and abdominis is clearly defined by the diaphragma, the separation between the cavitates abdominis and pelvis is often only demarcated by bony reference points on the body wall. Thus, the cavitates abdominis and pelvis essentially remain a single cavity, and therefore form a single region where disease processes can spread from one cavity to the other.

A mesenterium is a layer of connective tissue covered by peritoneum. Within it run the organ's neurovascular supply (vasa sanguinea and lymphatica, nervi). With reference to organs, the mesenterium is often identified with the prefix "meso" (e.g., mesocolon transversum).

C Spaces and body cavities and their respective organs in the thorax, abdomen, and pelvis

| Body cavity and the organs it contains | Serous cavities and the organs they contain | Serous membrane | Connective tissue spaces and their embedded organs |
|---|---|---|---|
| Cavitas thoracica (thorax) Thoracic organs | <ul style="list-style-type: none"> • Paired cavitates pleurales with pulmones: <i>Intrapleural organs</i> • Cavitas pericardiaca <i>Intrapericardial organ</i> | <ul style="list-style-type: none"> • Pleura visceralis and parietalis • Laminae visceralis and parietalis pericardii serosi | <ul style="list-style-type: none"> • Mediastinum (middle section of the cavitas thoracica) between the cavitates pleurales as well as behind the unpaired cavitas pericardiaca with the mediastinal organs: oesophagus, trachea, and thymus as well as vessels and nerves: – <i>Mediastinal organs</i> |
| Cavitas abdominis (abdomen) Abdominal organs | <ul style="list-style-type: none"> • Abdominal cavitas peritonealis with gaster (stomach), parts of the intestina tenue and crassum, splen (spleen), hepar (liver), vesica biliaris, and caecum with appendix vermiformis: <i>Intraperitoneal organs</i> | <ul style="list-style-type: none"> • Peritoneum viscerale and parietale | <ul style="list-style-type: none"> • Spatium extraperitoneale behind the abdominal cavitas peritonealis (spatium retroperitoneale, retropubicum) with renes, ureteres, pancreas and parts of the duodenum, intestinum crassum, and rectum: – <i>Extraperitoneal organs</i> |
| Cavitas pelvis (pelvis) Pelvic organs | <ul style="list-style-type: none"> • Pelvic cavitas peritonealis with fundus and corpus uteri, ovaria, tubae uterinae, and upper rectum: <i>Intraperitoneal organs</i> | <ul style="list-style-type: none"> • Peritoneum viscerale and parietale | <ul style="list-style-type: none"> • Spatia extraperitonealia behind and below the pelvic cavitas peritonealis (spatia retroperitoneale and subperitoneale) with vesica urinaria and adjacent portions of the ureteres, prostata, gll. vesiculosae, cervix uteri, vagina, and parts of the rectum: – <i>Extraperitoneal organs</i> |